

The early detection and management of ocular diseases

Challenges

Rachel North



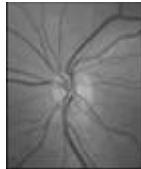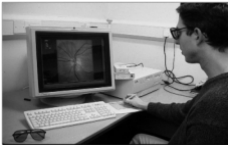
School of Optometry & Vision Sciences

Imaging techniques in the detection of glaucoma

- Optic nerve head photography
- Scanning laser ophthalmoscopy
- Nerve fibre layer analysis
 - GDx VCC Scanning Laser Polarimeter
 - Red free retinal photography
- Optical Coherence tomography

Digital imaging techniques

- Simultaneous stereo fundus photography
- Planimetric assessment



Sheen et al *Ophthalmology*, 2004
Morgan et al *Ophthalmology*, 2004
Morgan et al *Br J Ophthalmol*, 2005

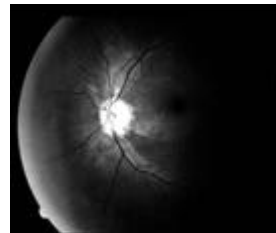
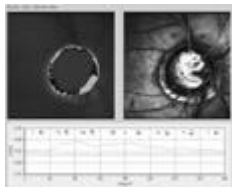
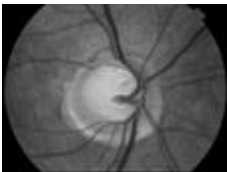
Scanning Laser Ophthalmoscopy

Heidelberg Retinal Tomograph

- A 670nm diode laser RASTER scans the fundus horizontally, vertically and through the retinal layers (x, y and z)



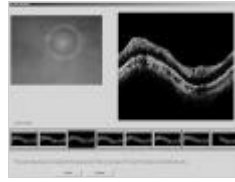

www.heidelbergengineering.com



RNFL - wedge defects visible by red free light

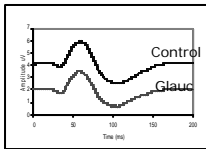
Optical Coherence Tomography

- An interferometric optical tomographic imaging technique

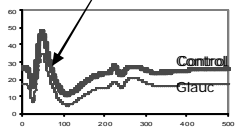


Function abnormal prior to structural loss in patients with high IOP

Pattern ERG



Photopic Negative Response

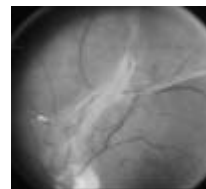
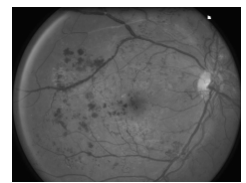
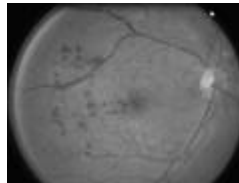
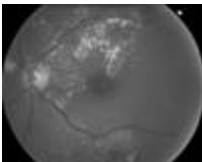


Drasdo et al IOVS, 2001
Aldebasi et al Vis Res, 2004

Treatment

- Topical drops – lower intraocular pressure
- Laser / surgical treatment
- Neuroprotective agents ?

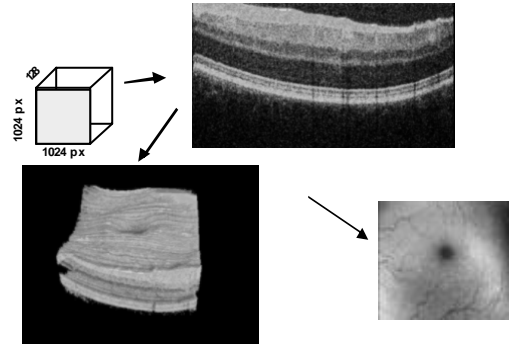
Diabetic Retinopathy



Detection of Diabetic Retinopathy

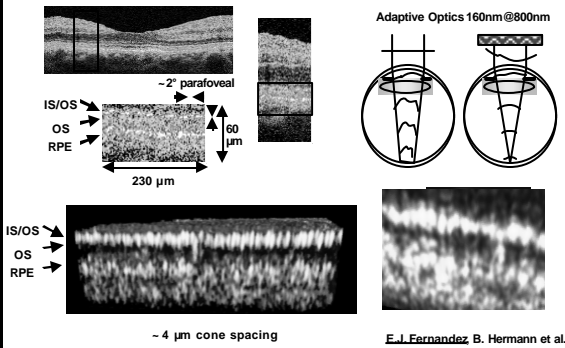
- Fundus photography
 - monoscopic and stereoscopic
- Scanning Laser Ophthalmoscopy – Retina module – Edema Index
- Optical coherence tomography
- Retinal Thickness Analyser
- Panoramic200 Optos

3D UHR OCT – Normal Human Fovea

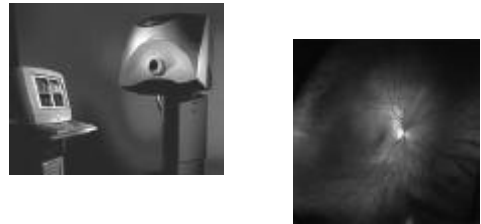


In vivo Cellular Resolution Retinal Imaging

Transversal resolution enhancement



Panoramic200 Optos



- Images from 2 lasers gathered separately
 - red relate to RPE and choroid
 - green relate to neural layers
- Resolution 20 μm centrally, 40 μm in far periphery

www.optos.com

Functional Loss

Occurs prior to visible diabetic retinopathy

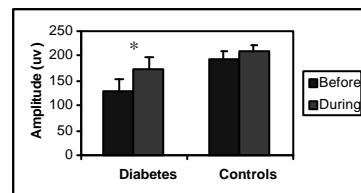
- Colour vision
- Contrast sensitivity
- Dark adaptation

With No Loss of visual acuity

North et al 1997, Diabetes Care
North et al 1997, Ophthal Physiol Opt

Is retinal dysfunction reversible?

Summed OP amplitudes before & during oxygen inhalation



Drasdo et al, Lancet 2002

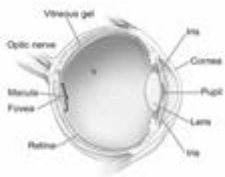
Management of Diabetic Retinopathy

- Glycaemic & hypertension control
- Laser treatment
- Anti angiogenesis drugs – Macugen , Lucentis etc
- Vitrectomy
- Oxygen inhalation for DMO?
- Steroid injections

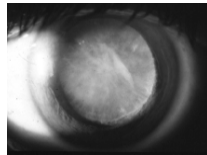
Early detection of diabetic retinopathy
- Screening & grading of images

Requirements?

- Digital simultaneous stereoscopic fundus camera
 - not currently available in EU
- Wide field stereo camera for general screening
- Detection of dysfunctional cells in vivo



National Eye Institute, National Institutes of Health

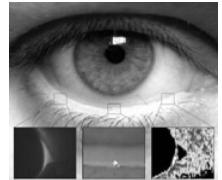


Accommodating IOL

Intraocular lens pressure sensor in experimental glaucoma

Tear Film Dynamics

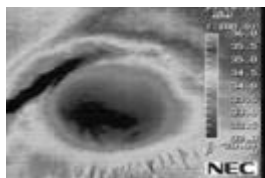
- Volume and stability
 - *Transparent fluid*
 - *Ever-changing*
 - *Non-invasive techniques preferred*
 - *Imaging challenge*
 - *Interferometry?*
 - *Thermal imaging?*




School of Optometry & Vision Sciences

Thermal imaging of the anterior eye

- A need for simultaneous measure of tear film thickness & ocular surface temperature



Tear ferning (TF)



- Graded patterns indicate tear film abnormalities
- Abnormal TF in dry eye is thought to be caused by tear film hyperosmolarity
- Simple test, but needs more objective analysis

Down's Syndrome Vision Research Unit Maggie Woodhouse

- Studying vision and visual deficits in children with DS since 1992
- Current study group of 180+ plus children from South and West Wales

Studies

- Longitudinal monitoring of acuity, refraction and accommodation
- Acuity and contrast sensitivity by sweep VEP
- Axial length and refraction
- Corneal topography
- Optic disc and retinal vessels dimensions

Problems

- Head rest – intimidating
- Appearance of instruments
- Fixation targets – boring for children
- eg for visual field examination target moves & child detect objects in periphery

Acknowledgements

- Denise Banford
- Una Whitcombe
- Katharine Mortlock
- Zohreh Chiti
- Rhianon Perrott
- Nasi Mahali
- Neville Drasdo
- David Owens
- Nik Sheen
- Ian Kelly
- Jennifer Cumiskey
- Adrian Jones

Support:

College of Optometrists, Diabetes UK, Leverhulme Trust, British Council for Prevention of Blindness, BUPA Foundation, The Wellcome Trust, Action Medical Research, UK & Eire Glaucoma Society